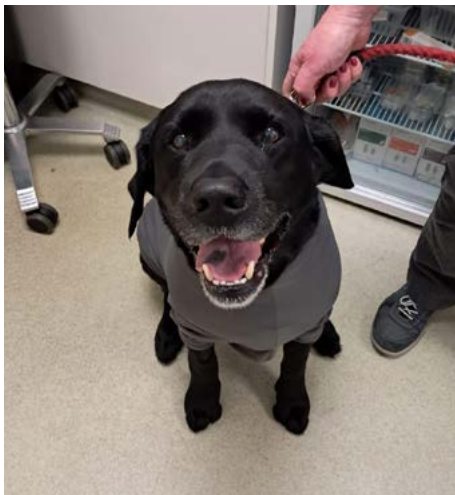

Focus on: Mass Removal & Reconstruction

Earlier this year, 10-year-old Labrador, Juno, was taken to his local practice for inspection of a mass that had been growing on the lateral aspect of his left stifle region.



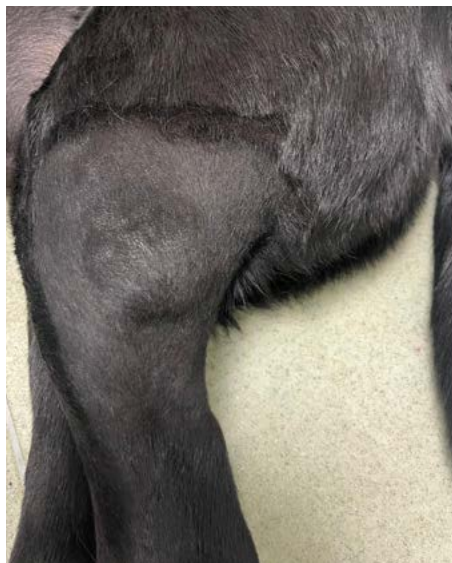The wonderful team at Juno's primary care practice had already performed extensive investigations ahead of contacting us for our help, including fine-needle-aspirates (FNA) which had led his referring vet to a diagnosis of a mast cell tumour. Although of low grade on FNA, this could not be confirmed without histopathology, nor could the team be sure whether any spread had occurred to other parts of Juno's body.

It was for this reason that steps were taken to assess for metastatic spread; starting off with ultrasound-guided biopsies of Juno's liver and spleen.

Abdominal organ examination was unremarkable at this stage, and cytology results did not support that there had been any metastasis, so this was a huge relief for Juno's family. Next up however, it was time for sentinel lymph node mapping, a technique used to assess the impact of a tumour on the lymphatic system. Juno was admitted for an anaesthetic which facilitated introduction of a contrast media around his mass, ahead of obtaining radiographs to analyse which lymph nodes were involved in his tumour growth. Again, to everyone's relief, results from this approach were positive, not highlighting any

metastasis to these areas, although similarly to the earlier FNA results, these findings could not be deemed 100% reliable.

Further to a thorough review of history by ProVetSurg soft tissue surgeon Sam, it was decided that mass removal with a reconstructive skin flap was in Juno's best interests.



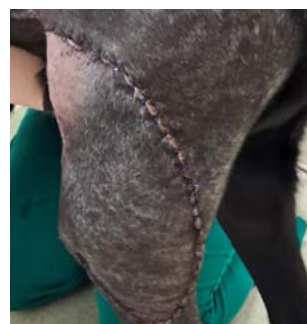
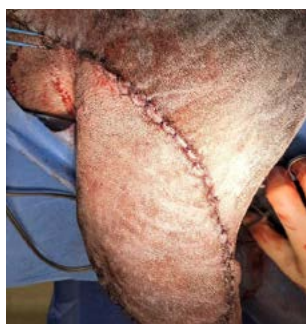
Sam approached the mass with wide margins, (removing the popliteal lymph node also), before employing an inguinal fold subdermal plexus flap to close the skin deficit. Juno took surgery in his stride, returning home later that day where he was cared for by his devoted Mum. Recovery was steady in the early days as Juno developed a small seroma under

his wound, a highlighted possibility with such surgery, although this didn't stop his mood from being bright, a quality he holds to this day.

Days after surgery, histopathology results returned confirming earlier suspicions of mast cell tumour which had in fact metastasised to the popliteal lymph node, highlighting the worth of removing this too. Sam and the practice continued to stay in touch about lovely Juno's recovery, leading us to receive wonderful news just over 3 weeks post-surgery

"The fabulous, wonderful, handsomest Juno has recovered well, and the flap is all covered by new hair growth. His mum is ever so pleased, and he is back to being a menace. I cannot thank Sam enough for all her wisdom, time and teaching. I really got a lot from scrubbing with her into the surgery and Juno is a very well-beloved dog at the practice (he can do no wrong in my eyes)." Agata – Small World Vets.

It has been a pleasure to work alongside Agata and her team at Small World Vets who have delivered exceptional care to Juno throughout his treatment journey, for which we are sure he is very grateful!



24/7 Reporting

We're proud to offer an around-the-clock advice service, providing our practices with feedback on radiographs and clinical histories, any day of the week, any time of day. If you have a case which you'd like to seek a second opinion on, please email info@provetsurg.co.uk or give us a call on 07852 440607 and we will respond to you within 24 – 48 hours. This service applies to all of your **orthopaedic, soft tissue and imaging** cases. You'll find on our website a list of all that we can offer but should your patient be in need of something outside of that list, **please do not hesitate to contact us** as our team hold a wealth of experience and would be very happy to advise you on the best route for your patient. Did you know we also host a specialist CT reporting service? Led by our surgeon Rob, this approach not only gives you information on a clinical picture but also provides various treatment options tailored to the individual's needs. Enquire today if you'd like to know more.

THANK YOU, from Edric!

Some of you will be aware that our surgeon, Edric, recently visited Malawi with the Worldwide Veterinary Service (WVS), to provide aid to those patients who otherwise may have gone without treatment. Thanks to the kindness of many of our practice teams, Edric travelled to Malawi with an abundance of donations, resulting in an upgrade to a heavier baggage allowance!



From unwanted medications to bandage materials, surgical instruments to second-hand crocs, we were truly overwhelmed by your generosity so **THANK YOU ALL** so much for donating to this very worthy cause. Edric and the team at WVS were exceptionally grateful for each donation which will really go a long way, in more ways than one! Follow us on our socials to catch updates from Edric's trip.

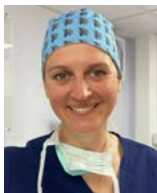The Wimba Way!

We've recently partnered up with [Wimba](#) to enable us to offer our patient's unique 4D-printed orthotics which are designed and manufactured easily and effectively using the Wimba app. This progressive technology captures limb conformation via a video which can be recorded on a mobile phone device, ahead of its analysis which leads to the creation of a custom-splint or support, ideal for giving clients the option of a non-surgical approach to conditions such as congenital or degenerative abnormalities. To find out more, head to the Wimba website and let us know if you think a patient in your care may benefit from being managed the Wimba way.



Meet our team

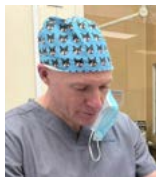This scoop, we wanted to share with you a fun fact about each of our team members!



Dr Nicci Meadows Surgeon

BVetMed CertAVP GSAS MRCVS

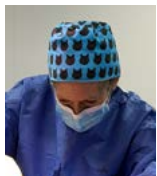Nicci is a member of the Veterinary Instrumentation advisory board which means she plays a vital role in the progression and development of future VI products.



Dr Dan Troup Surgeon

BSc (Hons) BVSc MRCVS

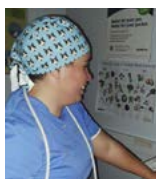Between work and studies, Dan is an avid cyclist, enjoying both on and off-road routes, preferably with a pub-pitstop!



Dr Sam Marshall Surgeon

MA VetMB CertSAS MRCVS RCVS
Recognised Advanced Practitioner
in Small Animal Surgery

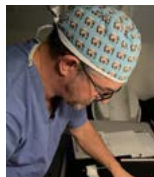
A lover of the countryside, Sam can be found on horseback in her spare time!



Dr Ana Afonso Ultrasonographer

DVM GPCert(DI) PgC(DI) MRCVS

Ana has a beloved cat called Seruga, who only has one eye! You can see Seruga featured on Ana's pet face scrub hat!



Dr Edric Cross Surgeon

BVetMed CertSAS MRCVS RVCS

When not busy operating, Edric loves painting – in particular animal portraits!



Dr Chris Nikolaou Surgeon

DVM CertAVP GSAS MRCVS

Chris adores learning and at present, is studying in Maths and Engineering!



Bev Morgan Surgical Nurse & Case Coordinator

RVN

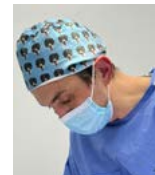Bev has 4 chickens called Margaret Hatcher, Chicoleta, Eggwina Curry and Chickpea.



Dr Heidi Burkinshaw Surgeon

BSc(Hons) BVetMed PgC(SAS) MRCVS

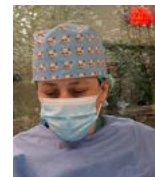Heidi enjoys an active lifestyle outside of work - her hobbies include surfing, running and Pilates!



Dr Ivan Filipovic Surgeon

DVM, PgC (SAS)

Ivan keeps busy in his spare time by attending Brazilian Jiu Jitsu training!



Dr Ana Murta Surgeon

MSc, PgC SAS, MRCVS

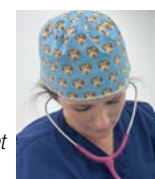When not out and about in practice, Ana loves to travel with her family, preferably somewhere that she can go scuba-diving!



Dr Rob Quinn Surgeon & Clinical Advisor

BVMS(Hons) CertAVP DipECVS MRCVS
Recognised & EBVS European Specialist
in Small Animal Surgery

A keen speaker, Rob kindly leads our monthly clinical clubs and M & M rounds.



Lauren Haighton Surgical Nurse & Case Coordinator

RVN CertVNECC

Lauren loves Guinea Pigs! At present she has 6 girls named Foxy, Bramble, Daisy, Maple, Blossom and Sweetie.

We are on Instagram, LinkedIn and Facebook – catch the latest news on our social pages

